



Peritoneal Inclusion Cyst with Entrapped Ovarian Syndrome: A Case Report

Asma Ali Depar¹, Anny Dhanwani², Aiman Majeed¹, Aimen Rehman¹, Rozilla Sadia Khan¹

¹Department of Obstetrics and Gynaecology, The Aga Khan University, Karachi, Pakistan

²Department of Community Health Sciences, The Aga Khan University, Karachi, Pakistan

ARTICLE INFO

Keywords: Peritoneal inclusion cyst, Entrapped ovary syndrome, Chronic pelvic pain, Adhesions, Ovarian cyst.

Correspondence to: Anny Dhanwani, Department of Community Health Sciences, The Aga Khan University, Karachi, Pakistan.

Email: anny.dhanwani@aku.edu

Declaration

Authors' Contribution: All authors equally contributed to the study and approved the final manuscript.

Conflict of Interest: No conflict of interest.

Funding: No funding received by the authors.

Article History

Received: 01-03-2025 Revised: 18-06-2025

Accepted: 02-07-2025 Published: 30-07-2025

ABSTRACT

Peritoneal inclusion cysts or pseudocysts of the peritoneum, are uncommon and noncancerous cystic growths that occur due to chronic irritation of the peritoneal lining, frequently developing after pelvic surgery, or as a sequela of surgical inflammation. We report the case of a 42-year-old female with a chronic history of abdominal surgeries who presented with chronic pelvic pain and bilateral flank pain. Other imaging studies showed a large multiloculated cyst in the vicinity of the ovary, periovarian cyst. She received hormonal therapy without relief. Surgical treatment was needed. Diagnosis was made during laparotomy and bilateral oophorectomy, which revealed PICs with Entrapped Ovary Syndrome. The patient's postoperative recovery was successful, and histopathology confirmed benign features. This case highlights the diagnostic challenges of PICs, the need for multimodal imaging in complex presentations, and underscores the importance of individualized surgical management, especially in patients with extensive adhesions or atypical clinical symptoms.

INTRODUCTION

Peritoneal inclusion cysts (PIC) also known as peritoneal pseudocysts, entrapped ovarian cysts or peritoneal inflammatory cysts occur as a result of the interference of abdominal adhesions with an active ovary(1, 2). In addition, be responsible for producing most peritoneal fluid while reproductive. However, in inflammatory conditions, infection or previous surgery can impair the absorptive capacity of the peritoneum, allowing exudative fluid from the ovary to become trapped between the ovary and adhesions post-ovulation(1, 3).

PICs non-neoplastic reactive mesothelial growth, it grows from 1 -3 cm. However, it is worthy to note that this syndrome has been reported in some adolescent female patients with previous surgery (particularly when displayed during infancy in the conditions like congenital genitourinary anomalies/ diaphragm defects(5); frequently represented by an acute onset of severe hypoventilation(4, 5). and symptoms may include abdominal pain-pelvic with severe nature (either acute or chronic) together with accompanying backache. Presentation may also be tenesmus, urinary incontinence

or frequency, anorexia, abnormal uterine bleeding and umbilical hernia(6, 7). PICs can be associated with chronic inflammatory conditions such as endometriosis, IBD and pelvic inflammatory disease (PID) (1, 8-10). However, 10% of PIC are diagnosed incidentally during imaging studies or surgery in asymptomatic patients. PIC usually presents as a multilocular, fluid-filled cystic lesion adjacent to the pelvic organs and attached to the ovary (8). Several studies have shown that most cases of PIC occur almost exclusively in women of childbearing age and in patients who have undergone abdominal or pelvic surgery(4, 11, 12).

According to the literature, PIC after laparoscopy is rarer than abdominal hysterectomy, and for the same reason, when considering surgical resection of PIC, laparoscopic resection is preferred over open surgery.

Though some studies have shown that PICs are treated with dinogest, which has been revealed to be very effective for this purpose (10, 13), the issue of treatment and diagnosis of PICs still requires further research(13). We here present a case of PIC diagnosed in a women of reproductive age group with prior history of abdominal

surgery with long standing history of multiple scars who presented with atypical clinical symptoms.

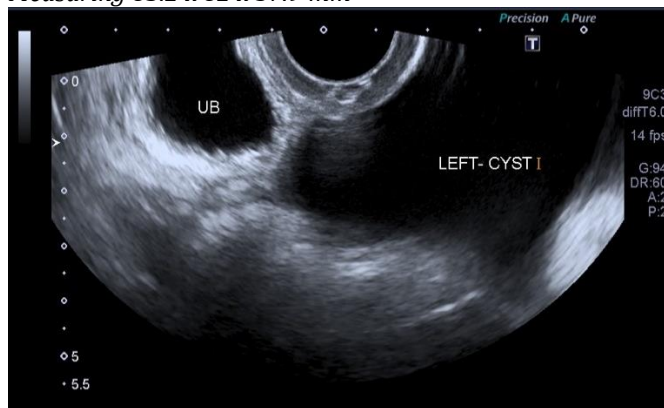
CASE REPORT

A 42-year-old, P5(LSCS), came in OPD on 1/1/2023 with complaints of bilateral flank pain for the last one month. Pain was intermittent, non-radiating and walking aggravated it whereas relief obtained only after consuming a tablet containing combination of Nubrol Forte. She had no significant past medical history. Her previous surgical history included five abdominal scars, and she had a total abdominal hysterectomy with bilateral salpingectomy in December 2021 for fibroid uterus. Family history is significant for Diabetes mellitus. And clinical examination was unremarkable.

She underwent an ultrasound for this pain, which revealed 83.2 x 82 x 57.9 mm left ovarian cysts that were thought to be endometriotic or hemorrhagic. Upon physical examination, she had no significant findings. They determine the diagnosis to be chronic pelvic pain.

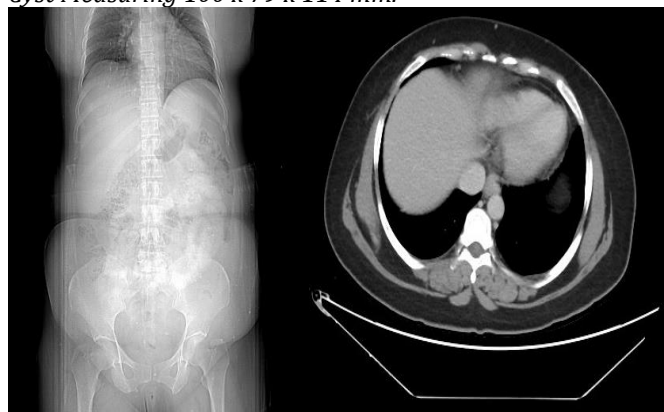
Figure 1

Ultrasound Pelvis Shows Left Adnexal Irregular Shaped Cyst Measuring 83.2 x 82 x 57.9 mm



Use of additional investigations demonstrated CA-125 at 6.1 IU/mL and CT abdomen/pelvis showed a large left adnexal cyst measuring 100 x 79 x 114 mm with a pelvic extension to the vaginal stump extending into the cul-de-sac between rectum and vaginal stump, likely representative of peritoneal inclusion cyst that was not enhancing in any phase. An additional right ovarian cyst was present with no evidence of the uterus, attributable to her known surgical history.

Figure 2 *Abdomen and Pelvis Show a Large Left Adnexal Cyst Measuring 100 x 79 x 114 mm.*



She was prescribed tablet Famila for two months for trial. A few months later she was reviewed again in opd but still in no better shape. Her repeat CT scan again demonstrated the presence of inclusion cyst. The patient was counselled regarding the options of CT-guided drainage versus laparotomy and opted to undergo surgery.

She underwent laparotomy and bilateral oophorectomy on 29/7/2024. Intraoperative findings included a midline infraumbilical incision with extension around the umbilicus, and omental adhesions to the anterior abdominal wall and sigmoid colon was attached to the vaginal vault. The right ovary was adherent to the lateral pelvic wall and the left ovary was adhered in the back side of urinary bladder as a part of peritoneal inclusion cyst (PIC) with Entrapped Ovary Syndrome.

During surgery, the right adnexal triangle is opened and ureter identified, then right infundibulopelvic ligament is clamped cut and ligated. The right ovary was mobilized from the right lateral wall. The left adnexal triangle was similarly opened, and the ureter identified and lateralized, with clamping, cutting of the left infundibulopelvic ligament. The right ovary was densely adherent to adhesions but was eventually removed, and the peritoneal inclusion cyst was also drained, and abdomen was similarly closed with ethanol and skin staples.

The patient remained stable postoperatively and was discharged on the third postoperative day. The patient was followed in the OPD, and wound staples were removed on 14th postoperative day. The histopathology report characterized benign findings. The patient was seen last at the end of September with a report that she was doing well.

DISCUSSION

PICs which develop from the peritoneal mesothelium, are a rare non-ovarian source of pelvic cysts (14). Considering the non-neoplastic condition, research indicates that they are reactive proliferation due to peritoneal shock caused by, pelvic inflammatory illness, endometriosis and abdominal surgery(4, 12, 15). Similarly, it is noted that the patient, in this case, presents pelvic inflammatory disease and past LSCS. PIC is usually found in women with an incidence rate of 82% in the female to male ratio of 4-5:1(8, 9). The peritoneal fluid has been seen to change with steroid hormones and also changes with the menstrual cycle in women: in the follicular phase peaking sharply at ovulation. Peritoneal inclusion cysts have been known to shrink after menopause and also with the use of combined oral contraceptives.(12).Most PICs are diagnosed by chance, but when they produce symptoms, they often manifest abdominal distension and pain(12). Pelvic pain, as presented in this case, is according to studies of the typical presenting symptom of PIC. PICs are mostly not palpable on the clinical examination like in our patient and hence imaging helps in the evaluation of these patients who usually present with abdominal or pelvic pain. Since they present with intermittent abdominal pain and typically in a patient with prior abdominal or pelvic surgery, mechanical bowel obstruction should be ruled out as a cause of pain 10% of small-sized PIC are incidentally detected(16). MRI is used together with ultrasound

imaging to further characterize complex cystic masses and to help establish relationships of anatomic types regarding other organs. Typically, successful treatments include interventional radiology or surgical resection in PIC. Treating can be carried out with the help of ultrasound imaging alone.(12). However, as seen in this case, the size and intricacy of the lesions, as well as the uncertainty regarding their source, necessitated additional imaging. Although the ultrasound result was of little help, a further CT scan and Ultrasound-guided aspiration yielded better result. Definitive diagnoses were acquired through the results from a histological examination. Asymptomatic cysts, especially those that are detected incidentally, do not need immediate intervention and can be managed conservatively. If the cases are symptomatic, options for management include hormonal therapy, drainage, or surgical excision(13). In this case, the patient was initially managed conservatively with hormonal therapy, which has been found to be not effective in treating PIC. However, when the patient's symptoms persisted, surgical intervention was deemed necessary. So, laparotomy with bilateral oophorectomy was performed to remove the adhesions and cysts, with the aim of alleviating pain and preventing recurrence. Studies suggest that laparoscopic

surgery may offer benefits in terms of recovery and lower postoperative complications compared to open surgery, but in cases where extensive adhesions are present, laparotomy may be the preferred option. Intraoperatively, extensive adhesions were noted between the ovary, pelvic wall, and omentum, all of which were addressed during surgery.

CONCLUSION

This case emphasizes careful clinical assessment of the patient, the role of advanced imaging techniques, and an approach to treatment that may need tailoring based on the degree of symptoms and cyst size. Optimization of diagnostic and therapeutic strategies for managing PICs remains an area to be explored, especially in those patients with complex surgical history and atypical presentations.

Data Availability

Data used to write this case report is accessible through contact with the corresponding author.

Consent

Informed consent was taken from the patient for participation in the study and publishing the results..

REFERENCES

- Jones SA, Salicco JM, Byers MS, editors. Pelvic pain and history of previous pelvic surgery. Baylor University Medical Center Proceedings; 2003: Taylor & Francis. <https://doi.org/10.1080/08998280.2003.11927892>
- Kim JS, Lee HJ, Woo SK, Lee TS. Peritoneal inclusion cysts and their relationship to the ovaries: evaluation with sonography. *Radiology*. 1997;204(2):481-4. <https://doi.org/10.1148/radiology.204.2.9240539>
- Jain KA. Imaging of peritoneal inclusion cysts. *American Journal of Roentgenology*. 2000;174(6):1559-63. <https://doi.org/10.2214/ajr.174.6.1741559>
- Amesse LS, Gibbs P, Hardy J, Jones KR, Pfaff-Amesse T. Peritoneal inclusion cysts in adolescent females: a clinicopathological characterization of four cases. *Journal of Pediatric and Adolescent Gynecology*. 2009;22(1):41-8. <https://doi.org/10.1016/j.jpog.2008.02.003>
- Goldfisher R, Awal D, Amodio J. Peritoneal inclusion cysts in female children: pathogenesis, treatment, and multimodality imaging review. *Case Reports in Radiology*. 2014;2014(1):427427. <https://doi.org/10.1155/2014/427427>
- Vallerie AM, Lerner JP, Wright JD, Baxi LV. Peritoneal inclusion cysts: a review. *Obstetrical & gynecological survey*. 2009;64(5):321-34. <https://doi.org/10.1097/ogx.0b013e31819f93d4>
- Nightingale K, Clough E, Goldsmith P, Burke JR. Peritoneal inclusion cyst presenting as an umbilical hernia: case report and systematic review of the literature. *Journal of Surgical Case Reports*. 2024;2024(5):rjae258. <https://doi.org/10.1093/jscr/rjae258>
- Kozasa K, Takemoto Y, Goto T, Kobayashi M, Sakaguchi H, Fujiwara S, et al. Two cases of giant peritoneal inclusion cysts requiring treatment after total laparoscopic hysterectomy. *Journal of Surgical Case Reports*. 2020;2020(12):rjaa506. <https://doi.org/10.1093/jscr/rjaa506>
- Moyle PL, Kataoka MY, Nakai A, Takahata A, Reinhold C, Sala E. Nonovarian cystic lesions of the pelvis. *Radiographics*. 2010;30(4):921-38. <https://doi.org/10.1148/rg.304095706>
- Miles S, Mansuria S. Multilocular Peritoneal Inclusion Cysts Throughout the Pelvis. *Journal of Minimally Invasive Gynecology*. 2021;28(9):1559-60. <https://doi.org/10.1016/j.jmig.2021.04.007>
- Gupta A, Kumar U, Mani R, Jain J, Singh A, Gupta S. Intraperitoneal Inclusion Cyst Presenting as Intestinal Obstruction: A Clinical Dilemma. *European Journal of Medical and Health Sciences*. 2020;2(3). <https://doi.org/10.24018/ejmed.2020.2.3.252>
- Stumpf L, Zinzuwadia S, Ploussard B, Zinzuwadia S, Brahmabhatt E, Adam K, Jawahar A. A case report on peritoneal inclusion cyst with entrapped ovary and an endometriotic cyst causing diagnostic dilemma. *International Journal of Reproduction, Contraception, Obstetrics and Gynecology*. 2022;11(4):1290. <https://doi.org/10.18203/2320-1770.ijrcog20220921>
- Natkanska A, Bizon-Szpernalowska MA, Milek T, Sawicki W. Peritoneal inclusion cysts as a diagnostic and treatment challenge. *Ginekologia Polska*. 2021;92(8):583-6. <https://doi.org/10.5603/gp.a2021.0142>
- Mehta V, Chowdhary V, Sharma R, Pernicka JSG. Imaging appearance of benign multicystic peritoneal mesothelioma: a case report and review of the literature. *Clinical Imaging*. 2017;42:133-7. <https://doi.org/10.1016/j.clinimag.2016.10.008>
- Pereira N. Postsurgical peritoneal inclusion cyst masquerading as a large pelvic mass. *BMJ Case Reports*. 2019;12(4). <https://doi.org/10.1136/bcr-2019-230066>
- Patel MD, Ascher SM, Paspulati RM, Shanbhogue AK, Siegelman ES, Stein MW, Berland LL. Managing incidental findings on abdominal and pelvic CT and MRI, part 1: white paper of the ACR Incidental Findings Committee II on adnexal findings. *Journal of the American College of Radiology*. 2013;10(9):675-81. <https://doi.org/10.1016/j.jacr.2013.05.023>